Thrombectomie Mechanique : Techniques et Recommandations

N.SOUROUR MD

Service de neuroradiologie. Unité de neuroradiologie interventionnelle.

Groupe Hospitalier Pitié-Salpêtrière. Paris. FRANCE





THROMBECTOMIE MÉCANIQUE : ASPECTS TECHNIQUES

www.saarsiu.com

Comment ré-ouvrir une artère : les différents mécanismes

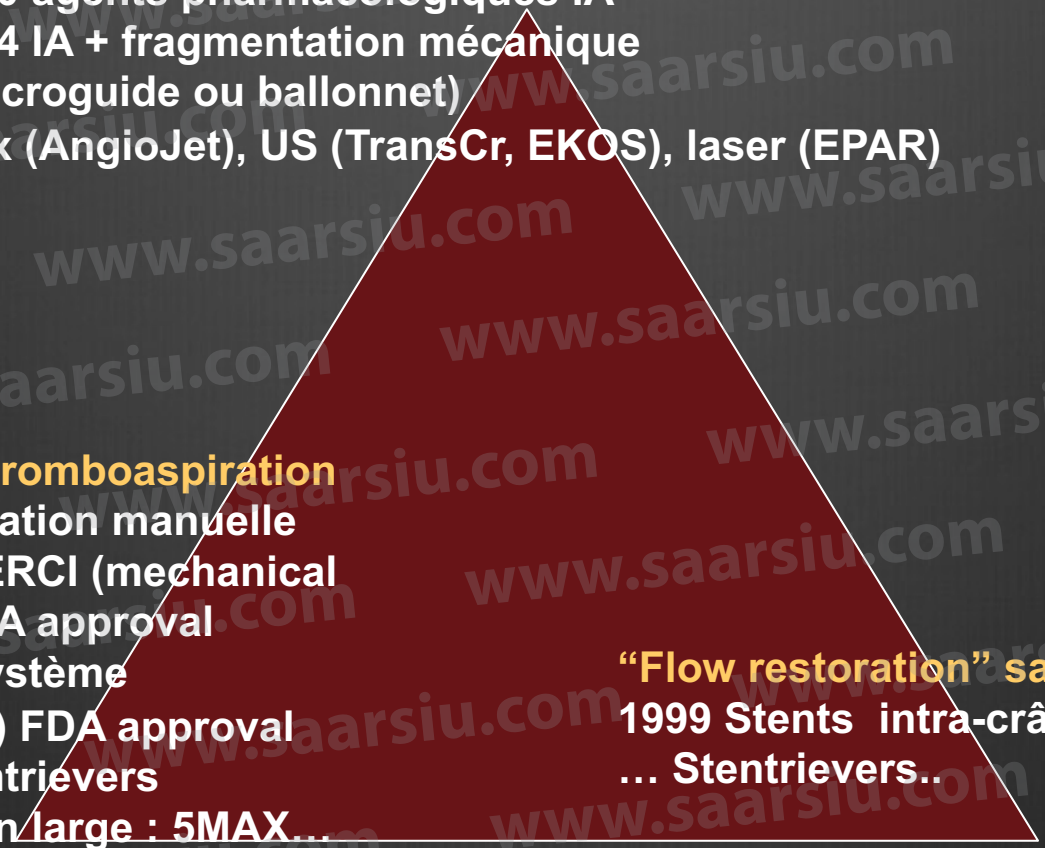

DISSOLUTION

Thrombolyse
1958 agents pharmacologiques IV
1980 agents pharmacologiques IA
1994 IA + fragmentation mécanique (microguide ou ballonnet)
Flux (AngioJet), US (TransCr, EKOS), laser (EPAR)

Thrombectomie/Thromboaspiration
2002 thromboaspiration manuelle
2004 Dispositif MERCI (mechanical thrombectomy) FDA approval
2007 Penumbra (système thromboaspiration) FDA approval
2008 Premiers stentrievers
…Cath. d'aspiration large : 5MAX…

"Flow restoration" sans retrait du caillot
1999 Stents intra-crâniens
… Stentrievers..

RETRAIT

BYPASS ENDOVASCULAIRE

NEJM n° mars 2013

The NEW ENGLAND JOURNAL of MEDICINE

ORIGINAL ARTICLE

Endovascular Treatment for Acute Ischemic Stroke

Alfonso Ciccone, M.D., Luca Valvassori, M.D., Michele Nichelatti, Ph.D., Annalisa Sgoifo, Psy.D., Michela Ponzio, Ph.D., Roberto Sterzi, M.D., and Edoardo Boccardi, M.D., for the SYNTHESIS Expansion Investigators*

ABSTRACT

BACKGROUND

In patients with ischemic stroke, endovascular treatment results in a higher rate of recanalization of the affected cerebral artery than systemic intravenous thrombolytic therapy. However, comparison of the clinical efficacy of the two approaches is needed.

METHODS

We randomly assigned 362 patients with acute ischemic stroke, within 4.5 hours after onset, to endovascular therapy (intraarterial thrombolysis with recombinant tissue plasminogen activator [t-PA], mechanical clot disruption or retrieval, or a combination of these approaches) or intravenous t-PA. Treatments were to be given as soon as possible after randomization. The primary outcome was survival free of disability (defined as a modified Rankin score of 0 or 1 on a scale of 0 to 6, with 0 indicating no symptoms, 1 no clinically significant disability despite symptoms, and 6 death) at 3 months.

RESULTS

A total of 181 patients were assigned to receive endovascular therapy, and 181 intravenous t-PA. The median time from stroke onset to the start of treatment was 3.75 hours for endovascular therapy and 2.75 hours for intravenous t-PA (P<0.001). At 3 months, 55 patients in the endovascular-therapy group (30.4%) and 63 in the intravenous t-PA group (34.8%) were alive without disability (odds ratio adjusted for age, sex, stroke severity, and atrial fibrillation status at baseline, 0.71; 95% confidence interval, 0.44 to 1.14; P=0.16). Fatal or nonfatal symptomatic intracranial hemorrhage within 7 days occurred in 6% of the patients in each group, and there were no significant differences between groups in the rates of other serious adverse events or the case fatality rate.

CONCLUSIONS

The results of this trial in patients with acute ischemic stroke indicate that endovascular therapy is not superior to standard treatment with intravenous t-PA. (Funded by the Italian Medicines Agency, ClinicalTrials.gov number, NCT00640367.)

The NEW ENGLAND JOURNAL of MEDICINE

ESTABLISHED IN 1812 MARCH 7, 2013 VOL. 368 NO. 10

Endovascular Therapy after Intravenous t-PA versus t-PA Alone for Stroke

Joseph P. Broderick, M.D., Yuko Y. Palesch, Ph.D., Andrew M. Demchuk, M.D., Sharon D. Yeatts, Ph.D., Pooja Khatri, M.D., Michael D. Hill, M.D., Edward C. Jauch, M.D., Tudor G. Jovin, M.D., Bernard Yan, M.D., Frank L. Silver, M.D., Rüdiger von Kummer, M.D., Carlos A. Molina, M.D., Bart M. Demaerschalk, M.D., Ronald Budzik, M.D., Wayne M. Clark, M.D., Osama O. Zaidat, M.D., Tim W. Malisch, M.D., Mayank Goyal, M.D., Wouter J. Schonewille, M.D., Mikael Mazighi, M.D., Ph.D., Stefan T. Engelter, M.D., Craig Anderson, M.D., Ph.D., Judith Spilker, R.N., B.S.N., Janice Carrozzella, R.N., B.A., R.T. (R.), Karla J. Ryckborst, R.N., B.N., L. Scott Janis, Ph.D., Renée H. Martin, Ph.D., Lydia D. Foster, M.S., and Thomas A. Tomsick, M.D., for the Interventional Management of Stroke (IMS) III Investigators

The authors' affiliations are listed in the Appendix. Address reprint requests to Dr. Broderick at the University of Cincinnati Neuroscience Institute, Department of Neurology, 260 Stetson St., Suite 2300, PO Box 670525, Cincinnati, OH, 45267-0525, or at joseph.broderick@uc.edu.

This article was published on February 7, 2013, and updated on March 7, 2013, at NEJM.org.

N Engl J Med 2013;368:893-903.
DOI: 10.1056/NEJMoa1214300
Copyright © 2013 Massachusetts Medical Society.

ABSTRACT

BACKGROUND

Endovascular therapy is increasingly used after the administration of intravenous tissue plasminogen activator (t-PA) for patients with moderate-to-severe acute ischemic stroke, but whether a combined approach is more effective than intravenous t-PA alone is uncertain.

METHODS

We randomly assigned eligible patients who had received intravenous t-PA within 3 hours after symptom onset to receive additional endovascular therapy or intravenous t-PA alone, in a 2:1 ratio. The primary outcome measure was a modified Rankin scale score of 2 or less (indicating functional independence) at 90 days (scores range from 0 to 6, with higher scores indicating greater disability).

RESULTS

The study was stopped early because of futility after 656 participants had undergone randomization (434 patients to endovascular therapy and 222 to intravenous t-PA alone). The proportion of participants with a modified Rankin score of 2 or less at 90 days did not differ significantly according to treatment (40.8% with endovascular therapy and 38.7% with intravenous t-PA; absolute adjusted difference, 1.5 percentage points; 95% confidence interval [CI], −6.1 to 9.1, with adjustment for the National Institutes of Health Stroke Scale [NIHSS] score [8–19, indicating moderately severe stroke, or ≥20, indicating severe stroke]), nor were there significant differences for the predefined subgroups of patients with an NIHSS score of 20 or higher (6.8 percentage points; 95% CI, −4.4 to 18.1) and those with a score of 19 or lower (−1.0 percentage point; 95% CI, −10.8 to 8.8). Findings in the endovascular-therapy and intravenous t-PA groups were similar for mortality at 90 days (19.1% and 21.6%, respectively; P=0.52) and the proportion of patients with symptomatic intracerebral hemorrhage within 30 hours after initiation of t-PA (6.2% and 5.9%, respectively; P=0.83).

CONCLUSIONS

The trial showed similar safety outcomes and no significant difference in functional independence with endovascular therapy after intravenous t-PA, as compared with intravenous t-PA alone. (Funded by the National Institutes of Health and others; ClinicalTrials.gov number, NCT00359424.)

The New England Journal of Medicine
Downloaded from nejm.org at ASSISTANCE PUBLIQUE HOPITAUX PARIS on March 11, 2015. For personal use only. No other uses without permission.
Copyright © 2013 Massachusetts Medical Society. All rights reserved.

The NEW ENGLAND JOURNAL of MEDICINE

ORIGINAL ARTICLE

A Trial of Imaging Selection and Endovascular Treatment for Ischemic Stroke

Chelsea S. Kidwell, M.D., Reza Jahan, M.D., Jeffrey Gornbein, Dr.P.H., Jeffry R. Alger, Ph.D., Val Nenov, Ph.D., Zahra Ajani, M.D., Lei Feng, M.D., Ph.D., Brett C. Meyer, M.D., Scott Olson, M.D., Lee H. Schwamm, M.D., Albert J. Yoo, M.D., Randolph S. Marshall, M.D., Philip M. Meyers, M.D., Dileep R. Yavagal, M.D., Max Wintermark, M.D., Judy Guzy, R.N., Sidney Starkman, M.D., and Jeffrey L. Saver, M.D., for the MR RESCUE Investigators*

ABSTRACT

BACKGROUND

Whether brain imaging can identify patients who are most likely to benefit from therapies for acute ischemic stroke and whether endovascular thrombectomy improves clinical outcomes in such patients remains unclear.

METHODS

In this study, we randomly assigned patients within 8 hours after the onset of large-vessel, anterior-circulation strokes to undergo mechanical embolectomy (Merci Retriever or Penumbra System) or receive standard care. All patients underwent pretreatment computed tomography or magnetic resonance imaging of the brain. Randomization was stratified according to whether the patient had a favorable penumbral pattern (substantial salvageable tissue and small infarct core) or a nonpenumbral pattern (large core or small or absent penumbra). We assessed outcomes using the 90-day modified Rankin scale, ranging from 0 (no symptoms) to 6 (dead).

RESULTS

Among 118 eligible patients, the mean age was 65.5 years, the mean time to enrollment was 5.5 hours, and 58% had a favorable penumbral pattern. Revascularization in the embolectomy group was achieved in 67% of the patients. Ninety-day mortality was 21%, and the rate of symptomatic intracranial hemorrhage was 4%; neither rate differed across groups. Among all patients, mean scores on the modified Rankin scale did not differ between embolectomy and standard care (3.9 vs. 3.9, P=0.99). Embolectomy was not superior to standard care in patients with either a favorable penumbral pattern (mean score, 3.9 vs. 3.4; P=0.23) or a nonpenumbral pattern (mean score, 4.0 vs. 4.4; P=0.32). In the primary analysis of scores on the 90-day modified Rankin scale, there was no interaction between the pretreatment imaging pattern and treatment assignment (P=0.14).

CONCLUSIONS

A favorable penumbral pattern on neuroimaging did not identify patients who would differentially benefit from endovascular therapy for acute ischemic stroke, nor was embolectomy shown to be superior to standard care. (Funded by the National Institute of Neurological Disorders and Stroke; MR RESCUE ClinicalTrials.gov number, NCT00389467.)

MR CLEAN

(Berkhemer OA. NEJM. 2015)



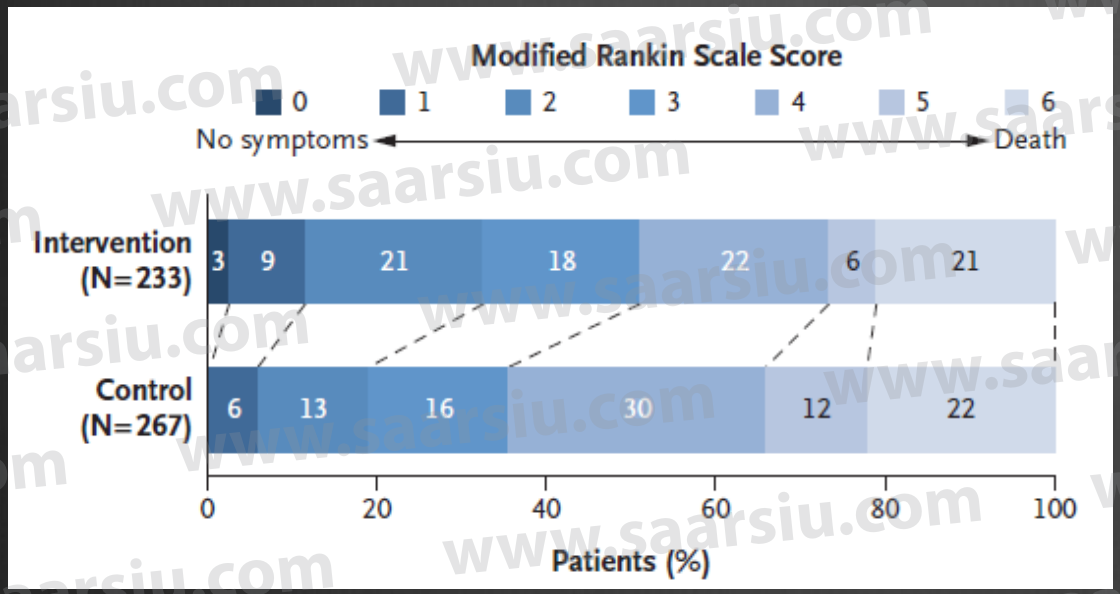

- Mortality: no significant difference
- Outcome: consistent better outcomes in favor of the intervention for all categories of the modified Rankin scale, except for death. 13.5 percentage points (95% CI, 5.9 to 21.2) in the rate of functional independence (modified Rankin score 0 to 2) in favor of the intervention (32.6% vs. 19.1%).

Ttt médical vs Ttt médical + TM

ESCAPE : + 23,7% en faveur TM
REVASCAT : + 15,5% en faveur TM
MR CLEAN : + 13,5% en faveur TM
EXTEND-IA : + 31% en faveur TM
SWIFT Prime : + 24,7% en faveur TM

www.saarsiu.com

Ce qui a changé:

- Sélection des patients: délai, occlusion proximale
- Stent retrievers









STENTRIEVERS



www.saarsiu.com

Stent + retriever = Stentriever
Stent ouvert dans le thrombus
Effet by-pass + retrait du caillot stent ouvert



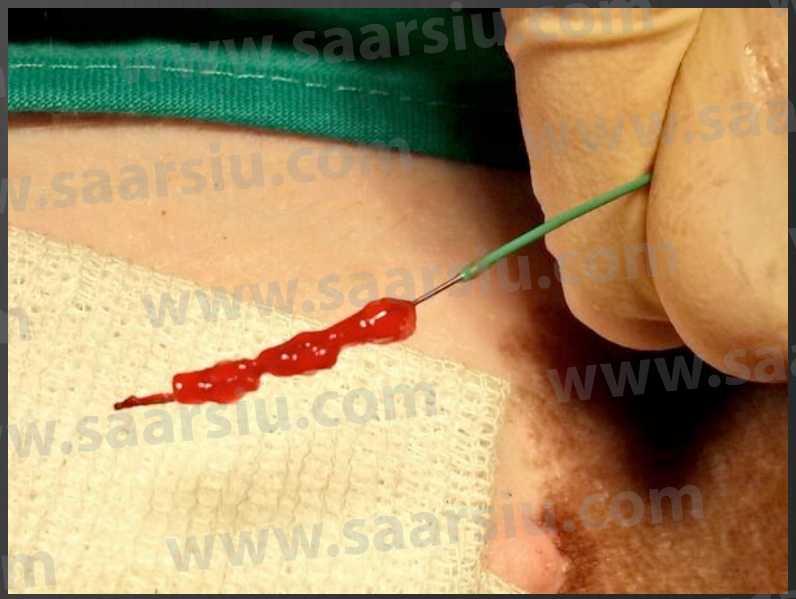

www.saarsiu.com


www.saarsiu.com

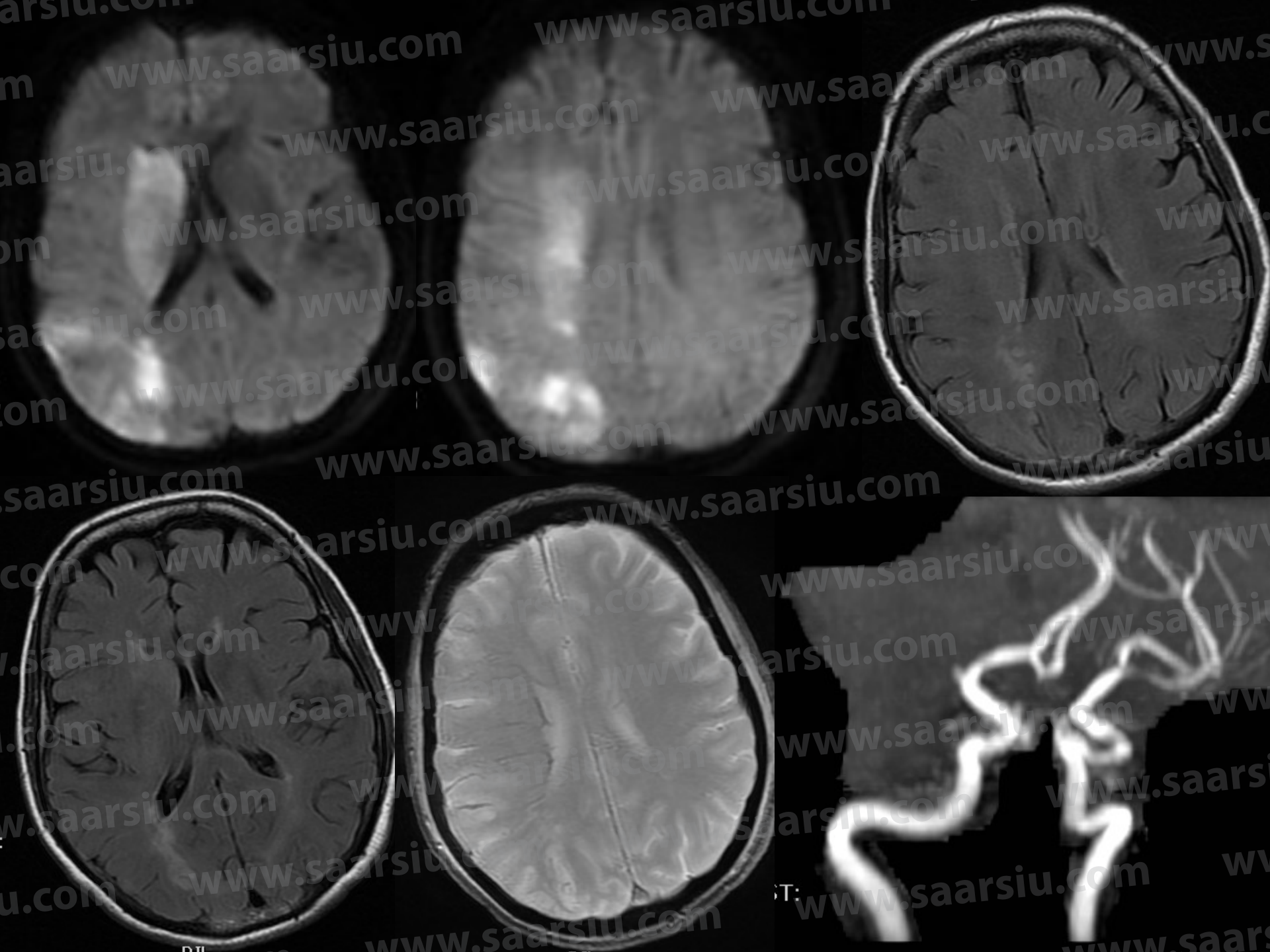
www.saarsiu.com

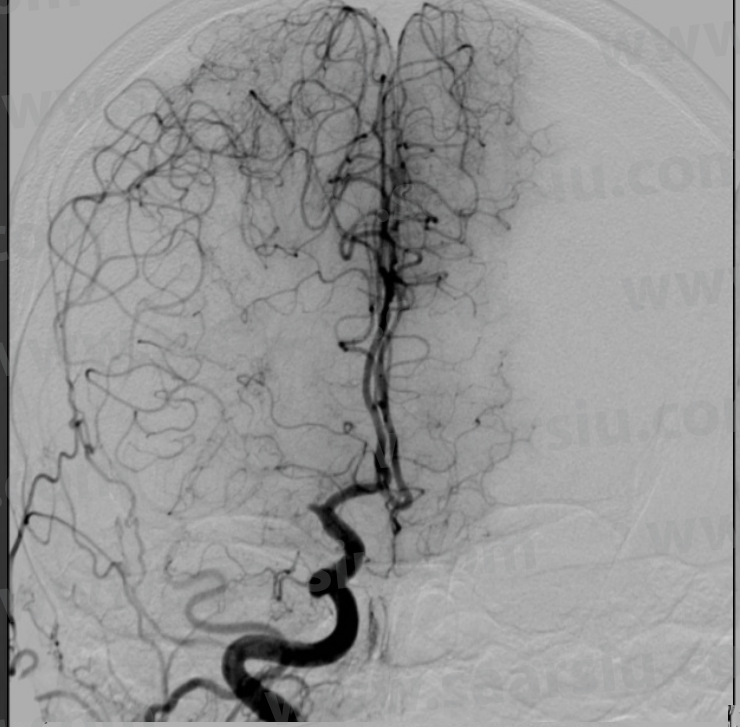





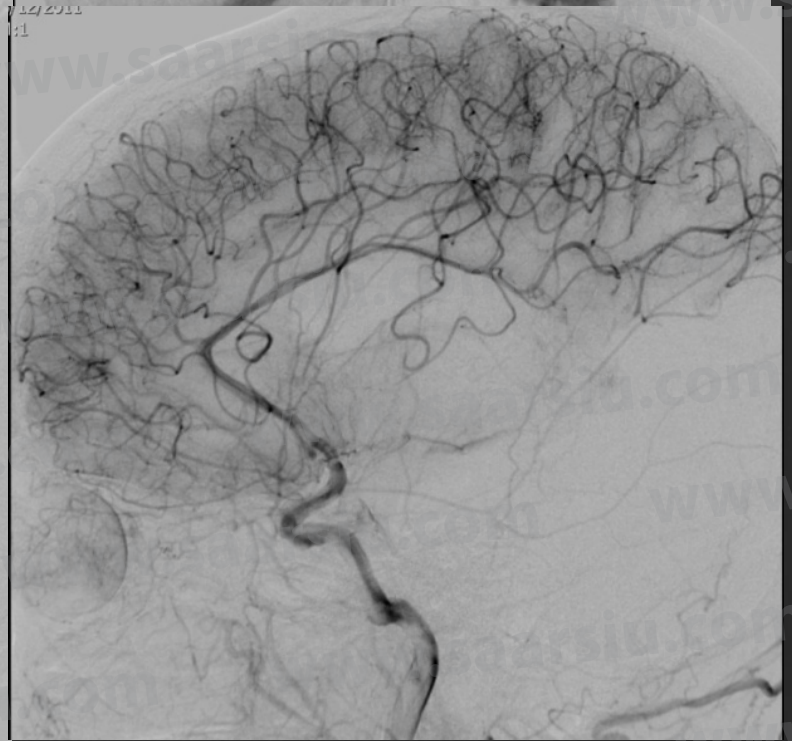


12/2011
300


/12/2011
:1


12/2011
300

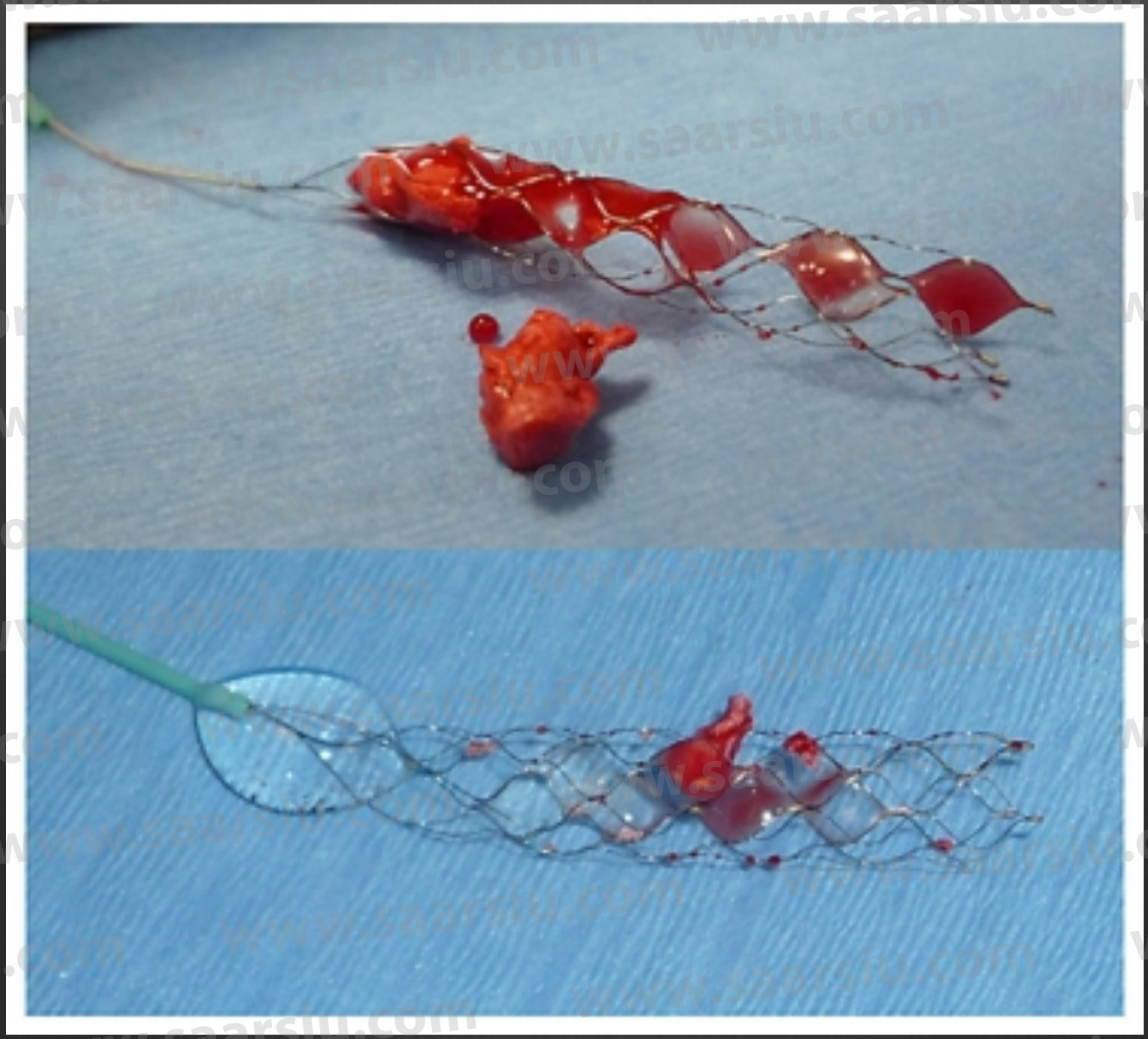


12/2011
1
control

THROMBO-ASPIRATION

www.saarsiu.com

- Montée d'un cathéter à large lumière au contact du caillot et aspiration
- Aspiration manuelle *(Vallee JN. Neurology. 2003)*
- Aspiration par pompe

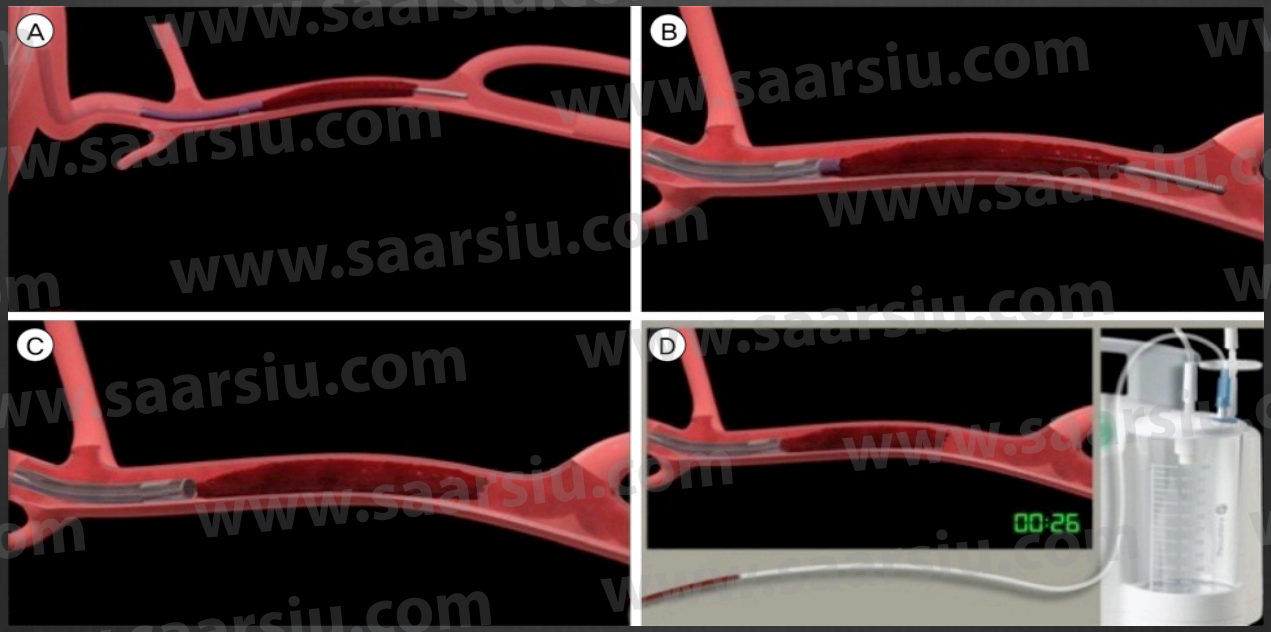

www.saarsiu.com



Patiente de 63 ans
Hémiplégie G
NIHSS = 12
patiente en salle d'angio à H7





www.saarsiu.com






POST THROMBOASPIRATION

INDICATIONS TM

www.saarsiu.com

Patients should receive endovascular therapy with a stent retriever if they meet all the following criteria *(Class I; Level of Evidence A).* (New recommendation):

a. Prestroke mRS score 0 to 1,

b. Acute ischemic stroke receiving intravenous r-tPA within 4.5 hours of onset according to guidelines from professional medical societies,

c. Causative occlusion of the ICA or proximal MCA (M1),

d. Age ≥18 years,

e. NIHSS score of ≥6,

f. ASPECTS of ≥6, and

g. Treatment can be initiated (groin puncture) within 6 hours of symptom onset

Recommandations AHA/ASA 2015 (Powers WJ. Stroke. 2015)

Règle des 6 :
- ≤ 6h
- ASPECTS ≥ 6
- NIHSS ≥ 6

www.saarsiu.com

Cas de figures hors recommandations

- Occlusions artère basilaire
- Occlusions distales (M2)
- Dissections/occlusions en tandem
- TM chez patients très âgés

www.saarsiu.com

ORIGINAL ARTICLE

Thrombectomy 6 to 24 Hours after Stroke with a Mismatch between Deficit and Infarct

Nogueira RG et al. NEJM. 2017

prospective randomised study (MT vs best Ttt médical)

Inclusion Criteria :

- between 6 - 24h begining of symptoms
  - ≥ 80 y, NIHSS ≥ 10, vol < 21 ml
  - < 80 y, NIHSS ≥ 10, vol < 31 ml
  - < 80 y, NIHSS ≥ 20, vol < 51 ml

www.saarsiu.com

Occlusion artère basilaire

www.saarsiu.com

Occlusion artère basilaire

- MR CLEAN : 0 patient
- SWIFT PRIME : 0 patient
- REVASCAT : 0 patient
- EXTEND-IA : 0 patient
- ESCAPE : 0 patient
- THRACE : 4 patients (2%)

www.saarsiu.com

- **Occlusions de l ’a. basilaire (OAB) = 6-10% des AVC par occlusion de gros vaisseaux**
  (**Israeli-Korn SD.** Isr Med Assoc J. 2010; **Voetsch B.** Arch Neurol. 2004)
- **Mortalité spontanée = 80-90 %**
  (**Mattle HP.** Lancet Neurol. 2011)
- **Handicap sévère: tétraparésie, locked-in syndrome**
  (**Schonewille WJ.** J Neurol Neurosurg Psychiatry. 2005)

Occlusions M2

www.saarsiu.com

Occlusion M2

- MR CLEAN : 39 patients (7,8%)
- SWIFT PRIME : 19 patients (10%)
- REVASCAT : 18 patients (9%)
- EXTEND-IA : 10 patients (14,3%)
- ESCAPE : 9 patients (2,9%)
- THRACE : 2 patients (1%)

www.saarsiu.com

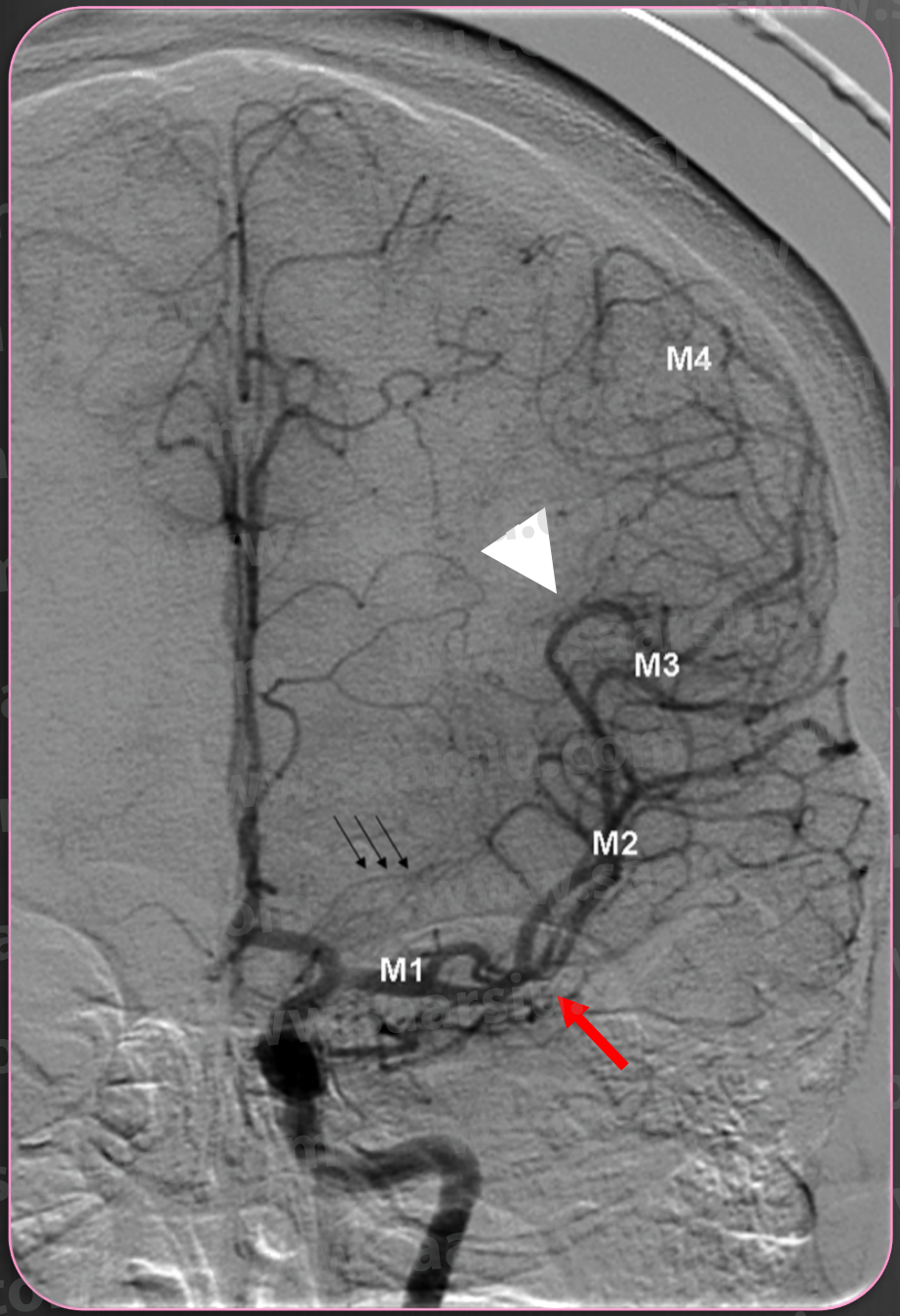

M1 (basal): Horizontal

Bifurcation (78 %)/trifurcation (12 %)

M2 (insulaire) : le long insula; ascendante

M3 (operculaire) : concavité crâniale

M4 (cortical) : longe le cortex

Genou de la sylvienne

Point sylvien angio.

a. lenticulo-striées

www.saarsiu.com

- Patient de 36 ans
- Aphasie brutale







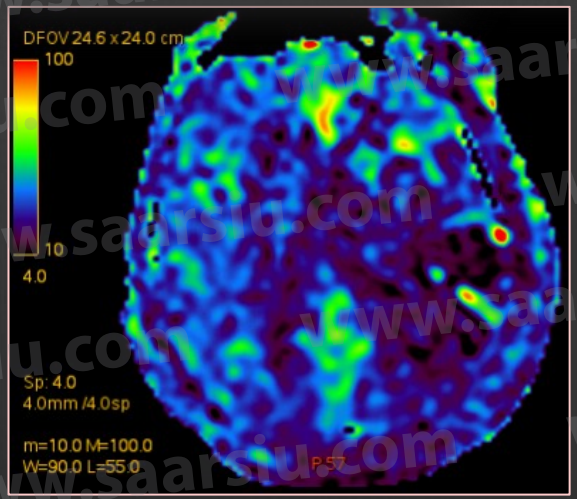

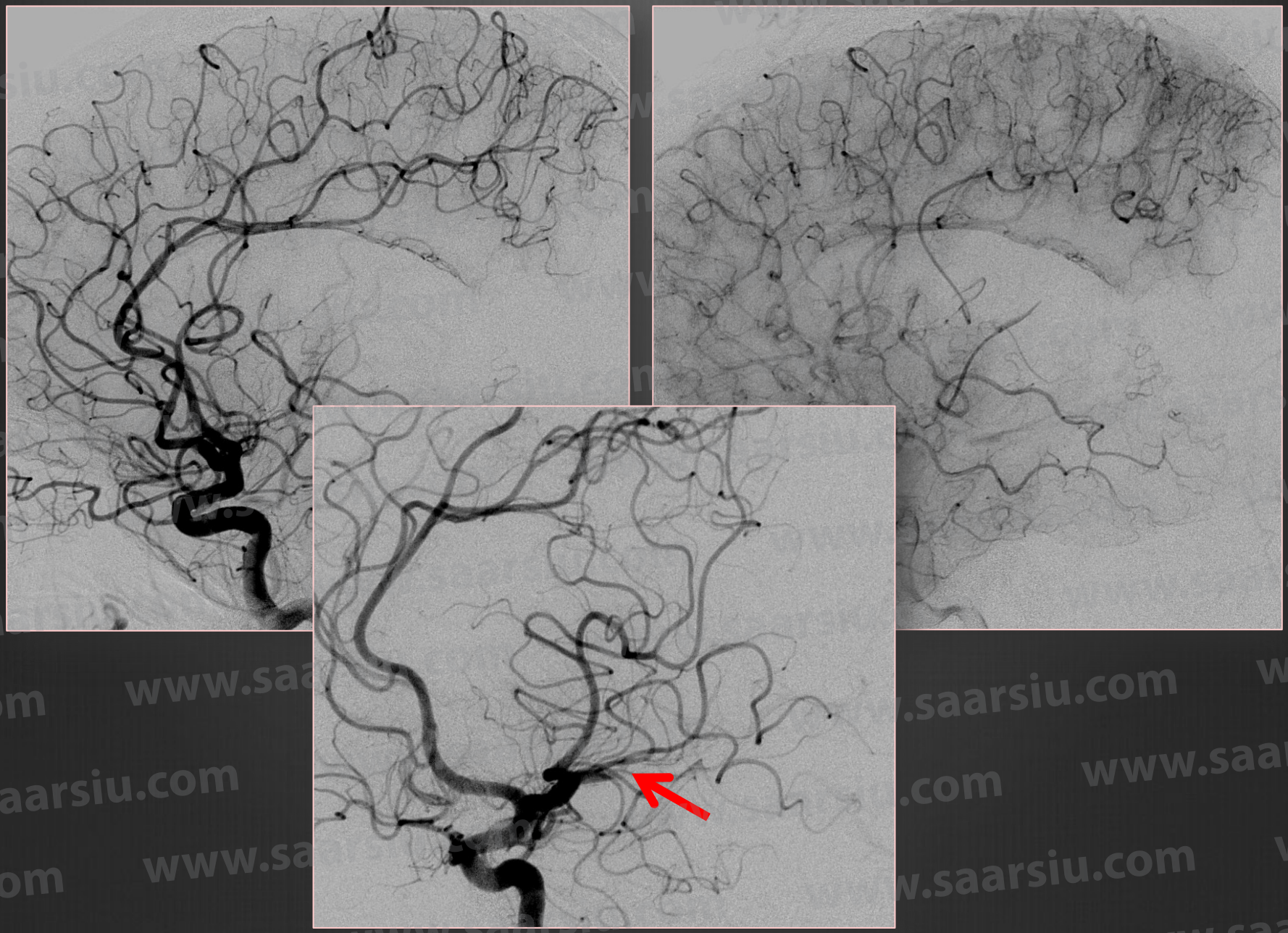



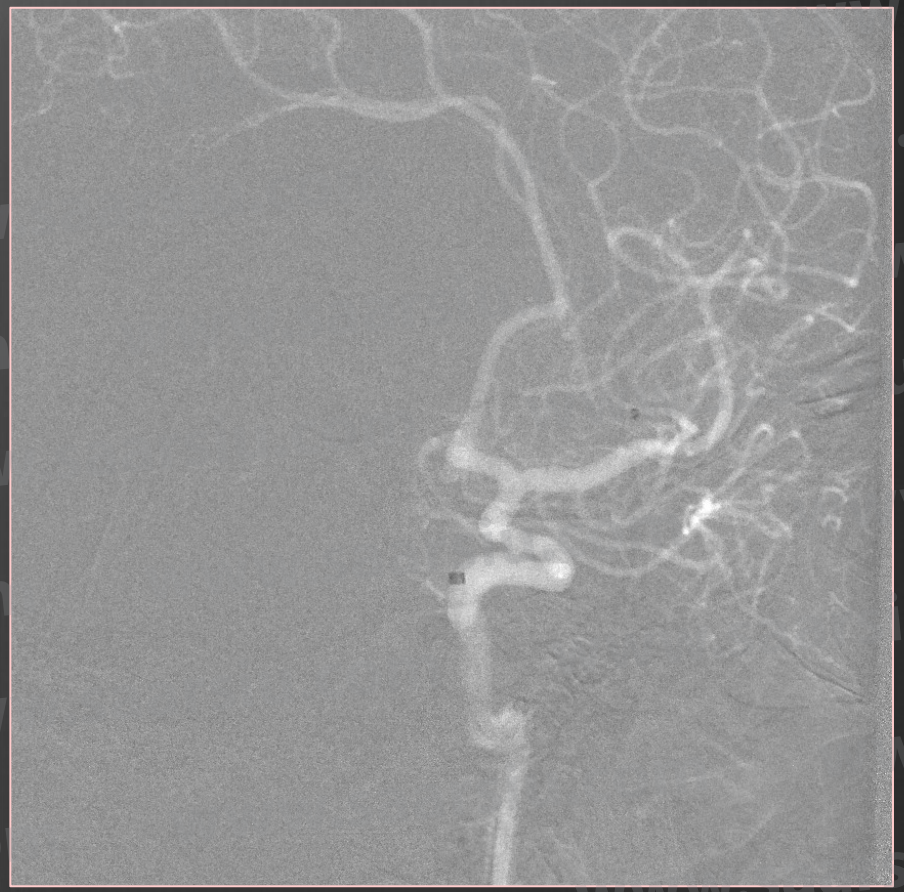

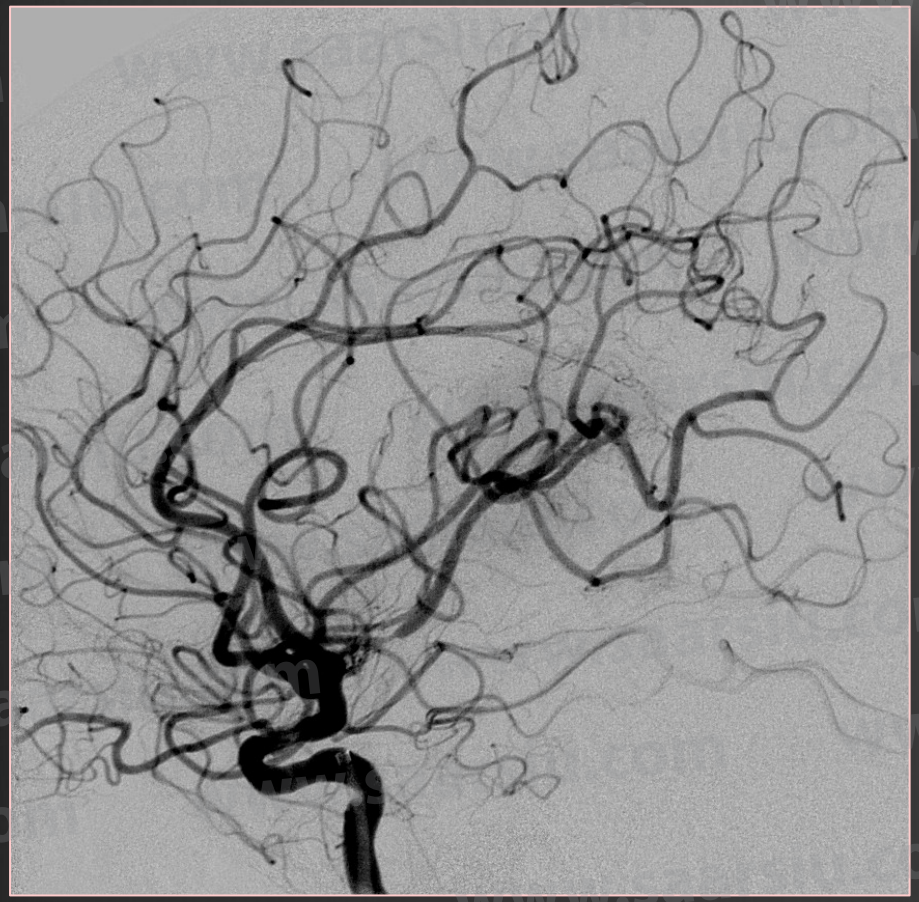



IRM de contrôle à H24

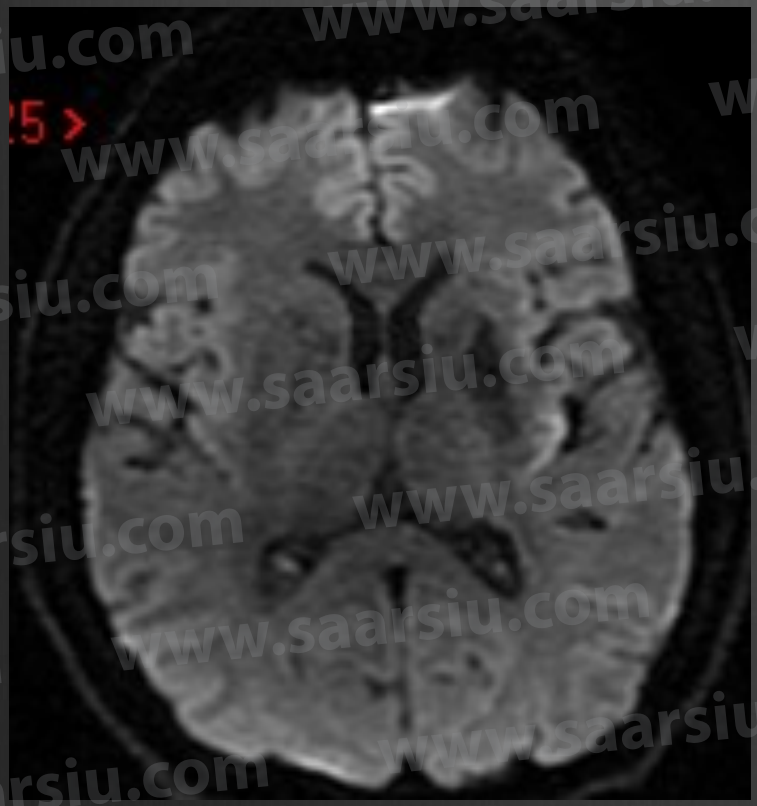

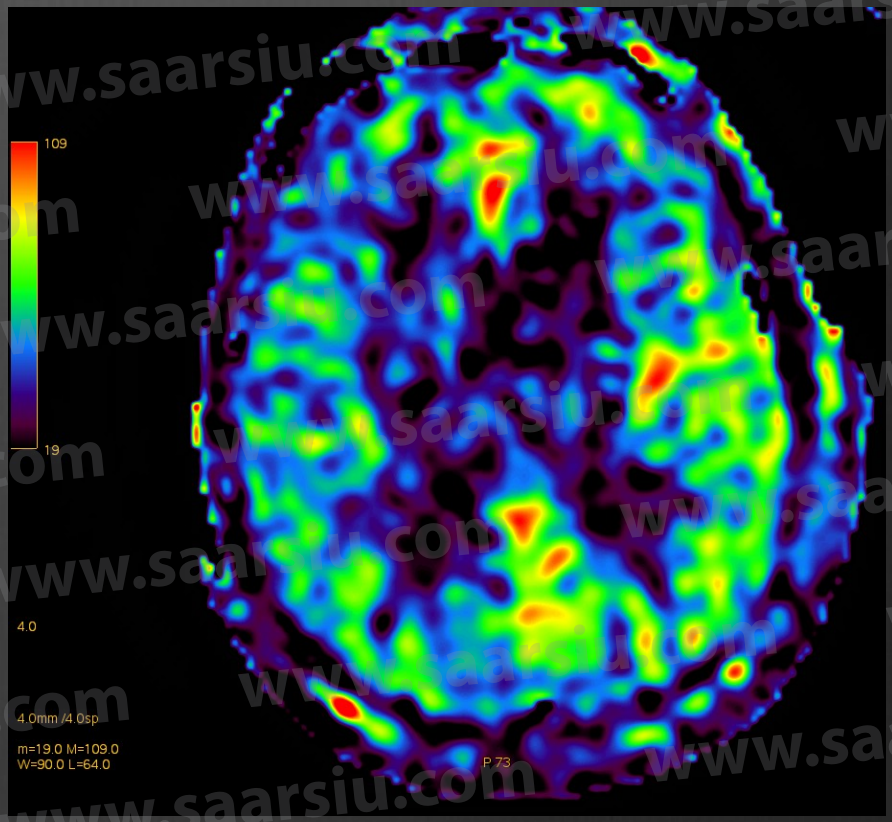

Techniques Combinées :
THROMBO-ASPIRATION
+
STENTRIEVER

www.saarsiu.com

- **Recanalisation (TICI 2B ou 3)** :

  - stentrievers : 75 à 90%
  - aspiration seule : 50 à 60%

- **Complications** :

  - oedema/hemorrage (reperfusion)
  - perforation
  - Migration caillot vers un territoire normal (5 à 10%)

www.saarsiu.com

Complications TM

www.saarsiu.com

God sees everything

but the neurologists miss no complication



ORIGINAL RESEARCH

Vessel perforation during stent retriever thrombectomy for acute ischemic stroke: technical details and clinical outcomes

Maxim Mokin,[1] Kyle M Fargen,[2] Christopher T Primiani,[1] Zeguang Ren,[1] Travis M Dumont,[3] Leonardo B C Brasiliense,[3] Guilherme Dabus,[4] Italo Linfante,[4] Peter Kan,[5] Visish M Srinivasan,[5] Mandy J Binning,[6] Rishi Gupta,[7] Aquilla S Turk,[8] Lucas Elijovich,[9] Adam Arthur,[9] Hussain Shallwani,[10] Elad I Levy,[10] Adnan H Siddiqui[10]

1599 cas de TM

1% de perforations

63% des perforations survenues sur TM distales

Mokin M. JNIS. 2016



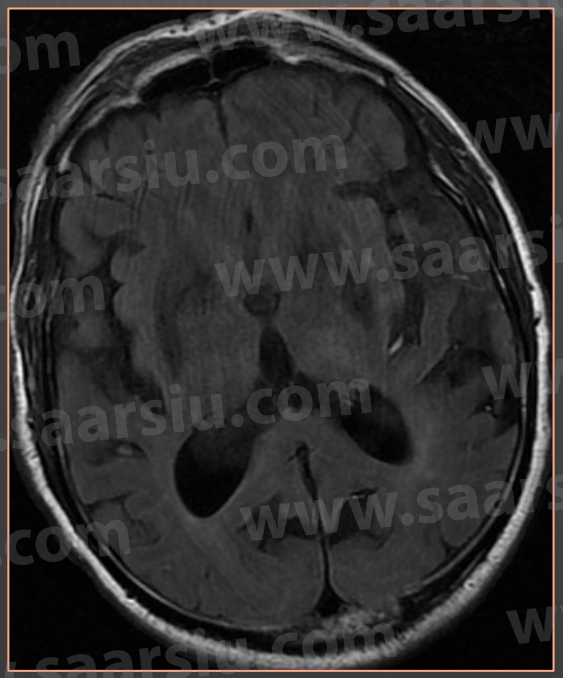

Patient de 65 ans
Aphasie au décours d'une coronarographie
Score NIHSS = 5
Patient sous Aspégic/ Plavix

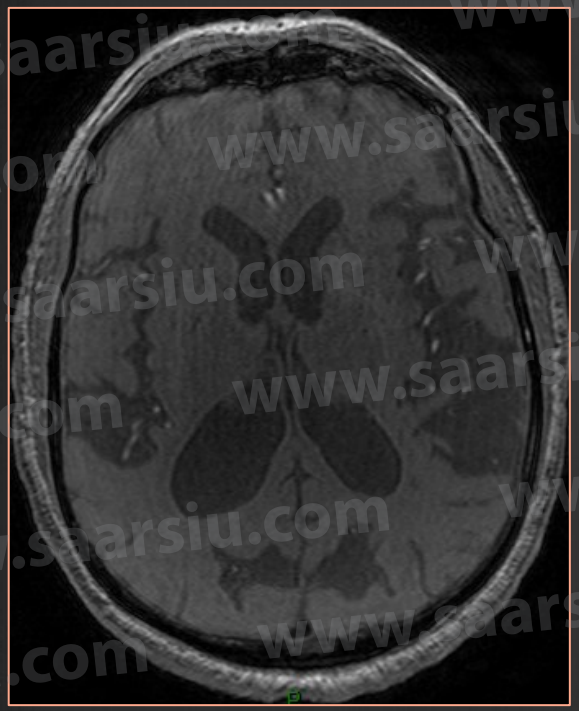





www.saarsiu.com

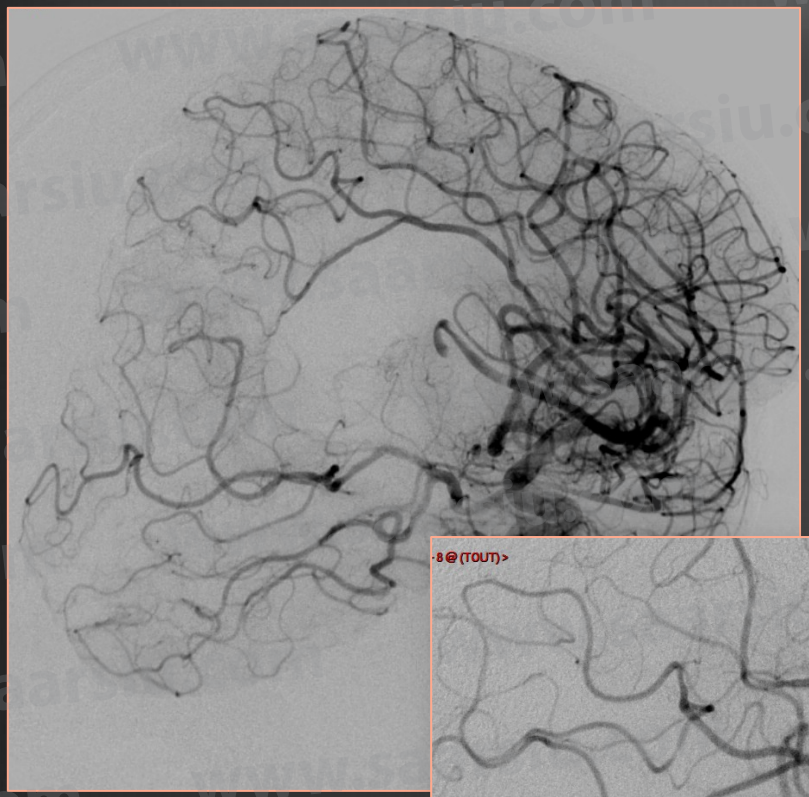



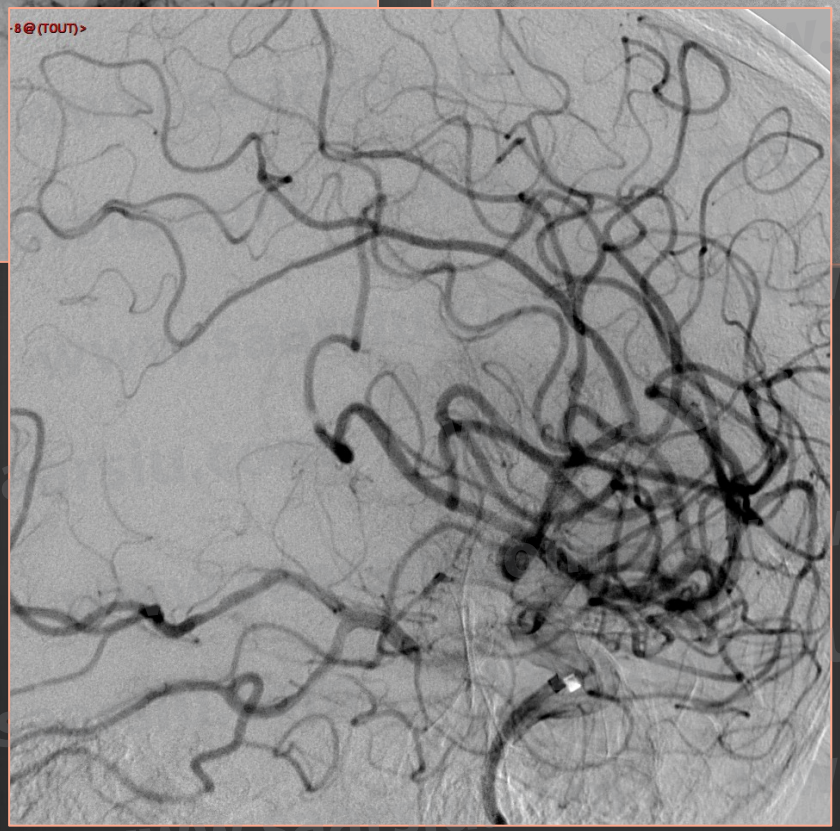

www.saarsiu.com

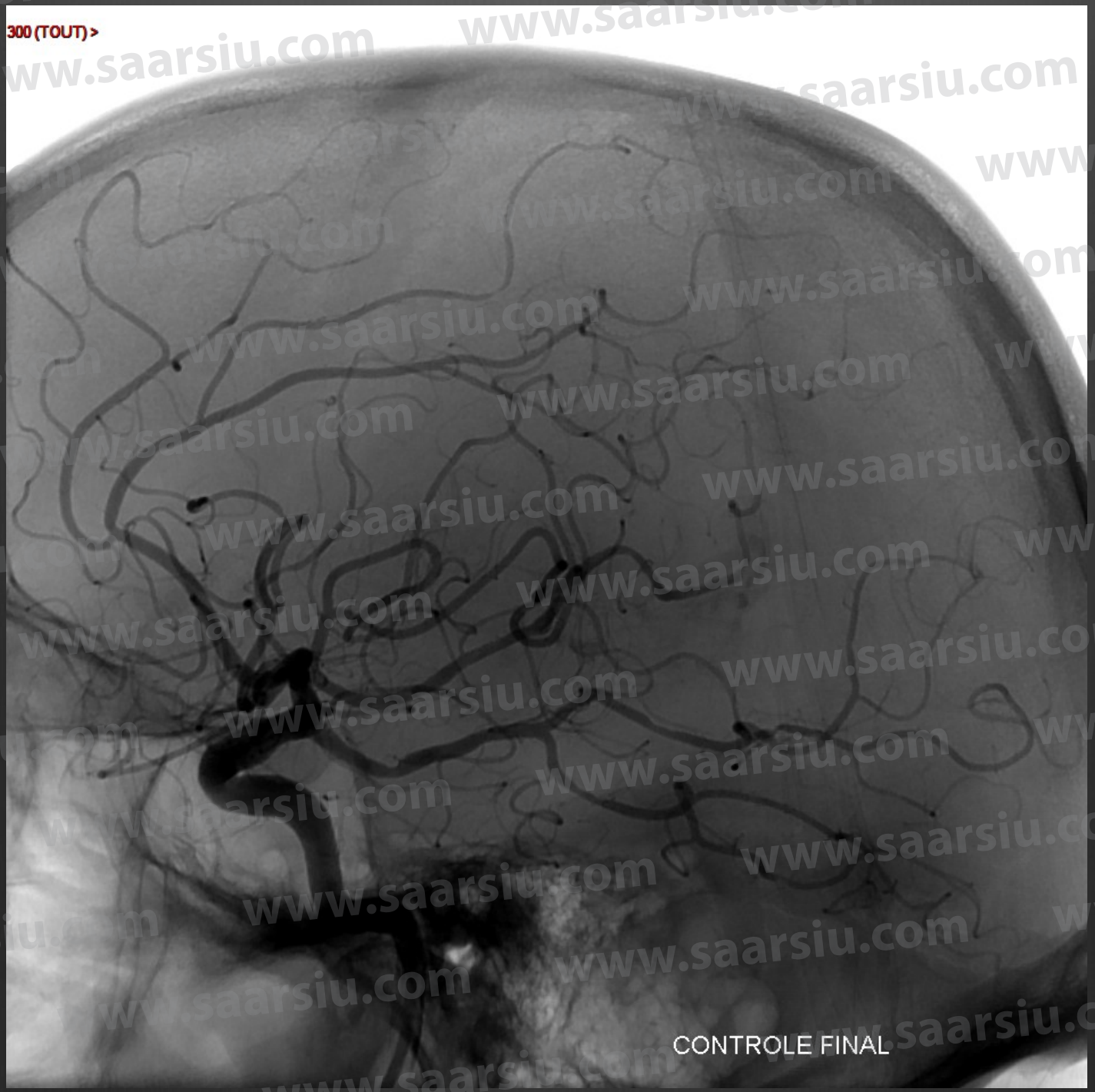
300 (TOUT) >
CONTROLE FINAL

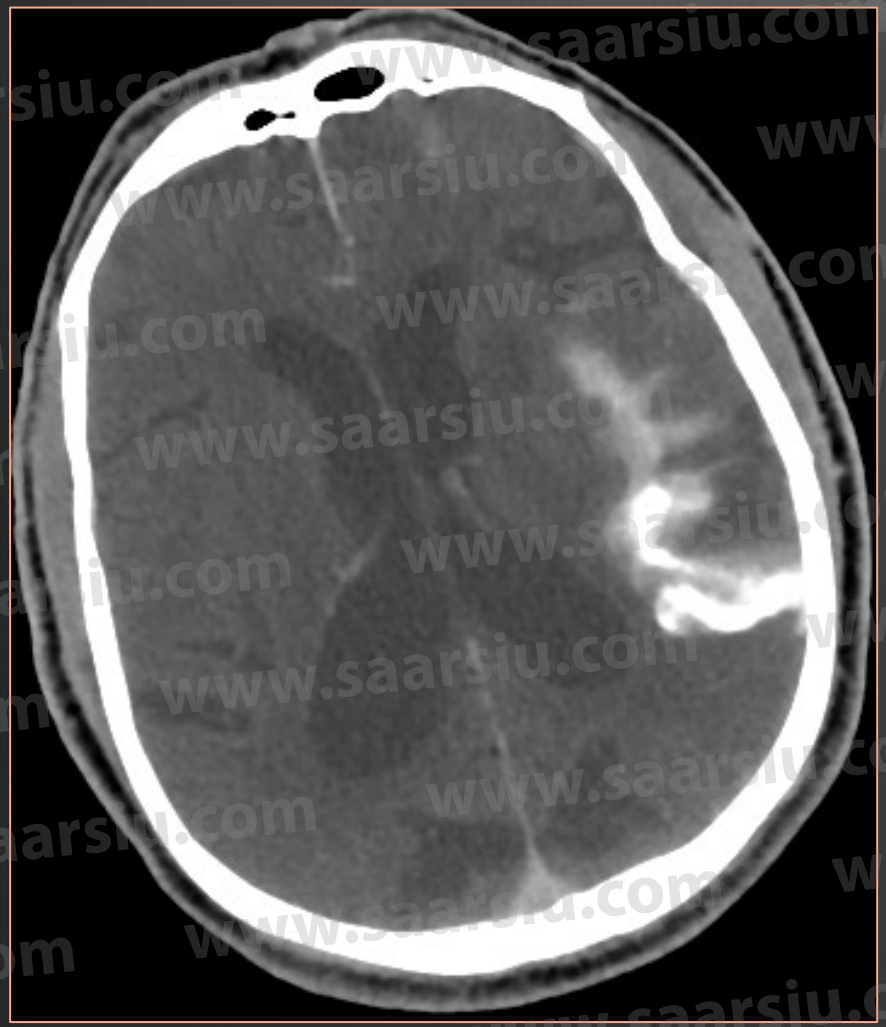



www.saarsiu.com

Dissections/occlusions en tandem

www.saarsiu.com

- MR CLEAN : 145 patients (29%)
- REVASCAT : 32 patients (15,7%)
- ESCAPE : 40 patients (18,6%)
- THRACE : 0 patients (0%)

www.saarsiu.com

TANDEM

- M 69
- Physical aggression with strangulation
- Hemiparesis
- Initial NIHSS = 12 rapidly deteriorated





www.saarsiu.com

TANDEM

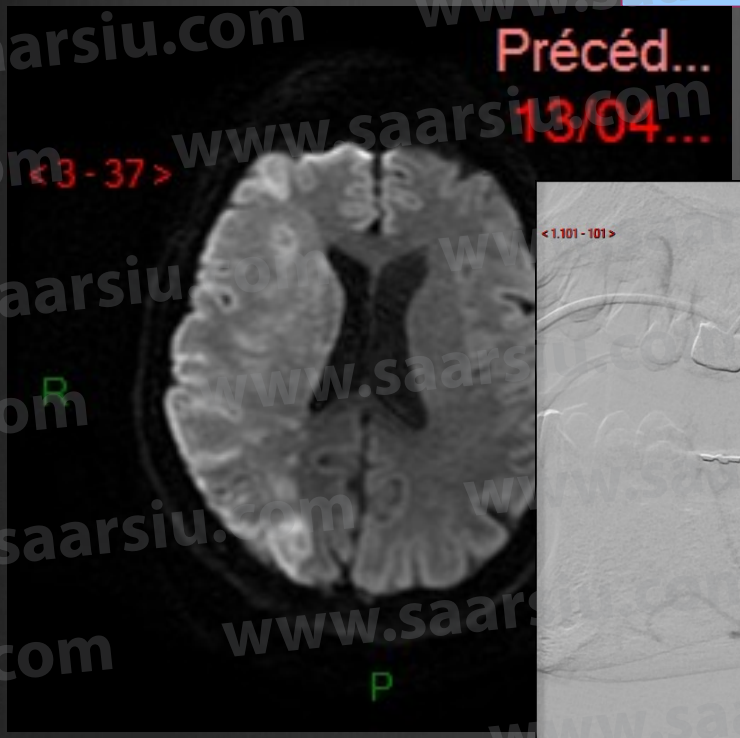
Précéd...
13/04...
< 3 - 37 >
R
P

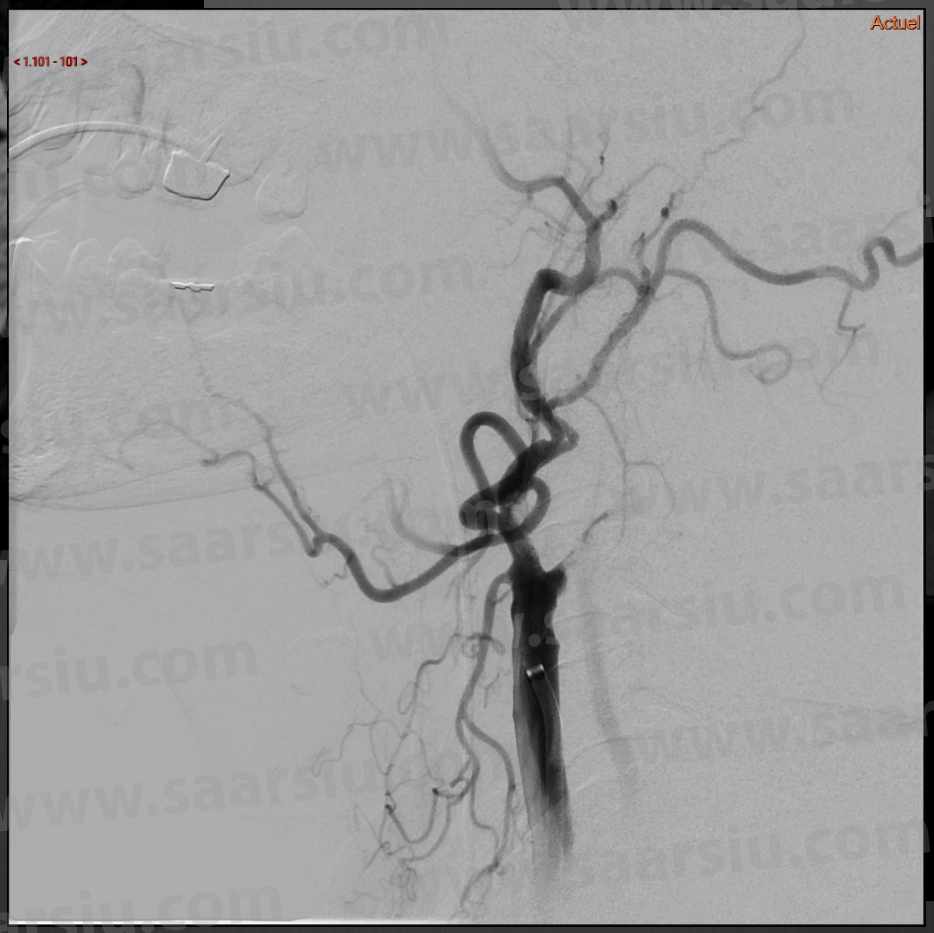
Actuel
< 1.101 - 101 >


SP
Précédent 1
13/04/2019 02:...
Ex:Apr 13 2019
L
IA

TANDEM



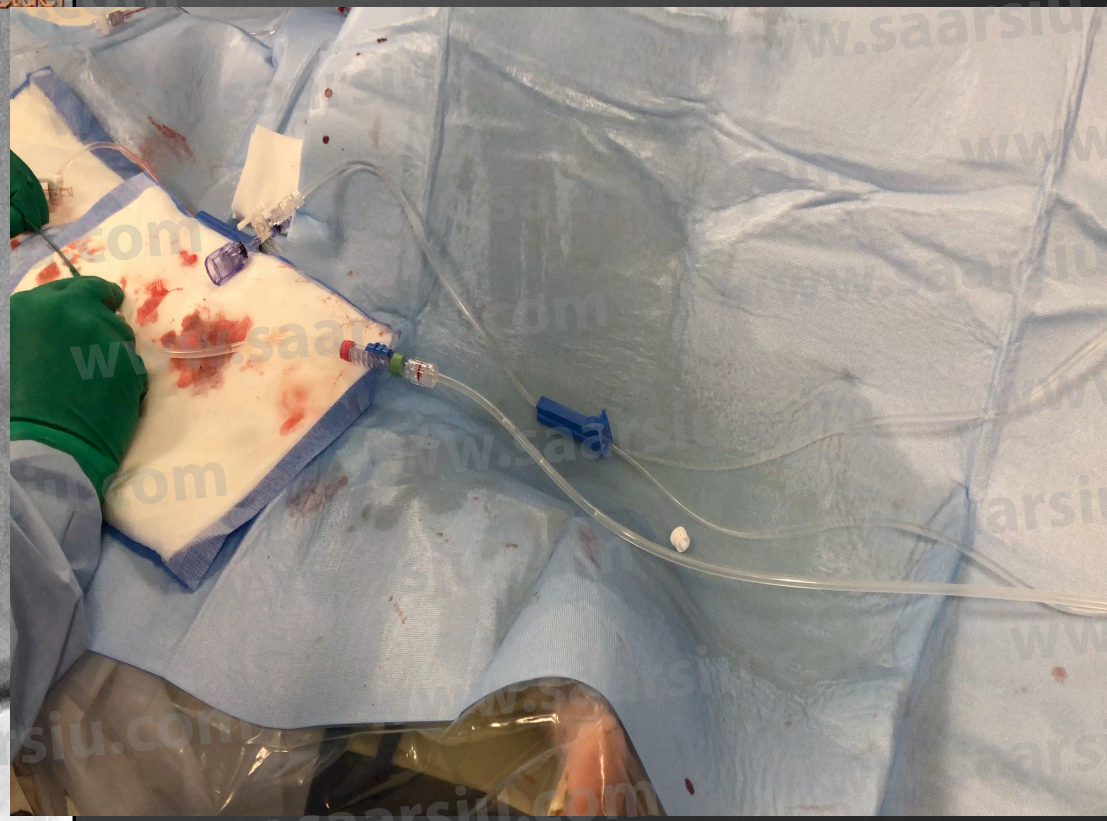

www.saarsiu.com

TANDEM



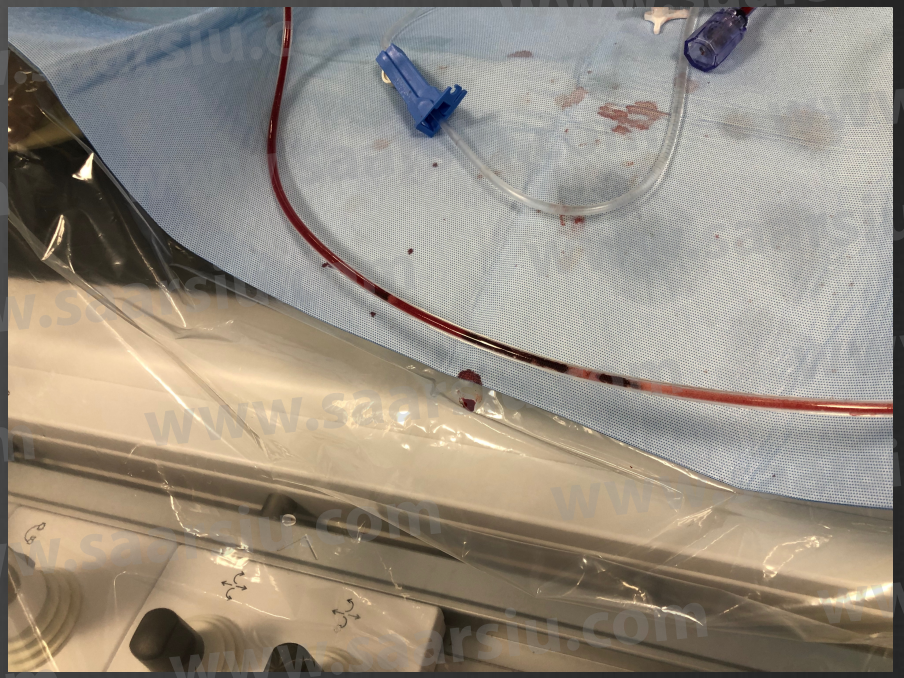

www.saarsiu.com

TANDEM





www.saarsiu.com

TANDEM





TICI 3

www.saarsiu.com

Score TICI

TICI Grade	Original TICI	Modified TICI	Modified TICI With 2c
0/1	No/minimal reperfusion	No/minimal reperfusion	No/minimal reperfusion
2a	Partial filling <2/3 territory	Partial filling <50% territory	Partial filling <50% territory
2b	Partial filling ≥2/3 territory	Partial filling ≥50% territory	Partial filling ≥50% territory
2c	…	…	Near complete perfusion except slow flow or few distal cortical emboli
3	Complete perfusion	Complete perfusion	Complete perfusion

TICI indicates thrombolysis in cerebral infarction.

www.saarsiu.com

« Take home » messages



- TM + Ttt médical optimal > Ttt médical seul
- L'âge avancé n'est pas une contre-indication à la TM
- Règle des « 6 » pour la circulation ant.
- Extension des indications : 6 à 24h ; études DAWN, DEFUSE 3

www.saarsiu.com

Merci pour votre attention



nsourour@gmail.com